

WORLD WIDE JOURNAL OF MULTIDISCIPLINARY RESEARCH AND DEVELOPMENT

WWJMRD 2022; 8(02): 19-21

www.wwjmr.com

International Journal

Peer Reviewed Journal

Refereed Journal

Indexed Journal

Impact Factor SJIF 2017:

5.182 2018: 5.51, (ISI) 2020-

2021: 1.361

E-ISSN: 2454-6615

DOI: 10.17605/OSF.IO/8S75V

Nang Khin Mya

Faculty of Medicine and
Health Sciences, University
Malaysia Sabah, 88400, Kota
Kinabalu, Sabah, Malaysia.

Aye Aye Wynn

Faculty of Medicine and
Health Sciences, University
Malaysia Sabah, 88400, Kota
Kinabalu, Sabah, Malaysia.

Tin Tin Thein

Faculty of Medicine and
Health Sciences, University
Malaysia Sabah, 88400, Kota
Kinabalu, Sabah, Malaysia.

Nay Myo Sitt

Forensic Department,
Mandalay General Hospital,
Mandalay, Myanmar.

Correspondence:

Nang Khin Mya

Faculty of Medicine and
Health Sciences, University
Malaysia Sabah, 88400, Kota
Kinabalu, Sabah, Malaysia.

Suicidal Hanging, is suicide true? A rare case report

Nang Khin Mya, Aye Aye Wynn, Tin Tin Thein, Nay Myo Sitt

Abstract

Hanging is one of the most common methods of suicide worldwide, and is increased in number of deaths by years. This report describes rare case of hanging which was done by the age of 10 year-girl as suicidal hanging of a child is very uncommon.

The investigating officer and forensic team immediately visited the crime scene and checked the possible foul play. Autopsy study supported the suicidal hanging with motive.

Keywords: hanging, suicide, youngest age, injuries, motives.

Introduction

Hanging is one of the 10-leading causes of death in the world and one of the most common methods of suicide. The materials necessary for suicide by hanging are readily available to the average person, the common age are adults between 20 to 40 years (Dinesh) and in England, suicide by hanging has increased markedly in males aged <65 years and females aged < 45 years. (David Gunnell). We presented the rare case of suicidal hanging by a 10 years old girl.

Case report

A 10 year-old girl was found dead in a solitary latrine dangling at the end of the towel acting as a rope. The latrine was neatly built at the left corner of the compound about 100 feet from the main house. The walls, roof and the door were made up of cheap second- hand corrugated iron sheet and were tightly secured. Bolting the door from outside was totally impossible. There was complete hanging from the roof of latrine and no signs of foul play.

Observations

The scene, ligature material tied around the neck and injuries were shown in figures



Fig, 1: The scene of completed hanging in secured place.



Fig. 2: Ligature used (towel).

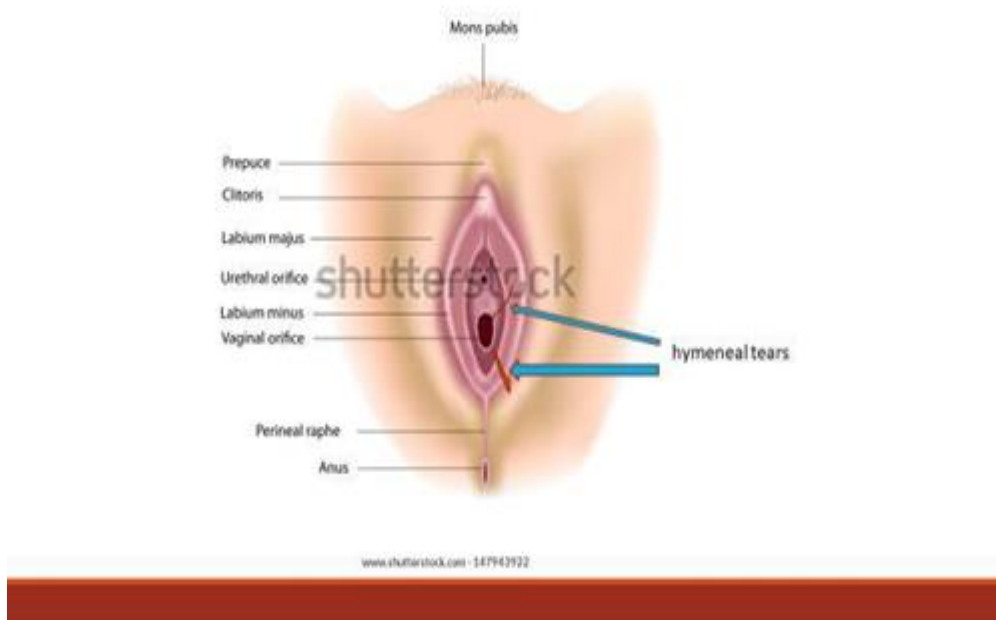


Fig.3: Circumferential bruises and hymeneal tears at 1 & 5 o'clock position.

Autopsy study

External:

There were no external injuries noted.

Internal:

The neck structures were intact. There was no bruising of the strap muscles, no intimal tear of the carotid vessels and no fracture of laryngeal cartilages and hyoid bone. Serial photographic recordings of these negative findings were taken.

Injuries:

On examining the genitalia; there were circumferential bruising of the hymen and upper part of vaginal wall with tearing of the hymen at 1 and 5 clock positions.

Results of autopsy study

The cause of death was opined as "suicidal hanging with the evidence of recent penetration of her private parts".

Forensic evidence observed on the scene of incident

The dead body of the deceased was found in a solitary

latrine dangling at the end of the towel acting as a rope

The latrine was locked from the inside

There was absence of disruption of the scene

Conclusion

Majority of victims of suicidal hanging were of single, females and it occurs indoor using clothes as a tool with increased incidence of cases in 20-30 years age group, yet this victim is 10 years old.

The cause of death was determined by very thorough autopsy which also involved the dissection of skins and was complemented by additional examinations including toxicological tests. The presented study underlines the significance of conducting a thorough autopsy and the necessity of corroboration of autopsy results with other investigation findings.

The usual motives were patients with substance abuse, anxiety, or personality disorders. Hopelessness was

positively associated with a stated wish to die and with escape motives, and negatively correlated to communicating/unclear motives. Suicidal intent was related to some motives. In this case, the victim was living with her aunt, she told her guardian aunt that she was visiting to her widow mother who was living together with another man. After the day end, her aunt found out that her niece didn't go to her mother's residence and they searched her and found dead.

Acknowledgments

The author is thankful to the forensic department for providing autopsy report and timely supports for successful investigation.

Ethical consent

None.

Conflicts of interest

The author declares there are no conflicts of interest.

References

1. Aisha A. Abouhashem, Suhib M. Bataw at al. Suicidal, homicidal and accidental hanging: comparative cross-sectional study in aljabal alakhdar area, libya. Zagazig J. Forensic Med. & Toxicology. Vol. (18) No. (1) Jan 2020
2. Department of Health. National suicide prevention strategy for England. London: Department of Health, 2002.
3. Gunnell D. Keith H at al. The epidemiology and prevention of suicide by hanging: a systematic review. International Journal of Epidemiology 2005. 34:433-442.
4. Nath S, Majumder R, Pratihari HK. Homicide hanging—a rare case report. Forensic Research & Criminology International Journal, Forensic ResCriminol Int J. 2020; 8(1):8–9.
5. Skoqman K, Aqneta Q. Motives for suicide attempts-the views of the patients, [https:// www.tandfonline.com](https://www.tandfonline.com) p 193-206 Nov 2010